



Thermal Imaging Services

Patient's Name	██████████	Report Date	12/09/2009
Patient ID	PriPat17031964	Study Date	12/04/2009
Date of Birth	03/17/1964	Thermographer	Kathy Markham, CCT
Referring Practitioner	Patrick Price, DC	Reporting Physician	Jeanne Stryker MD

PHYSICIANS INSIGHT INITIAL FULL BODY MALE STUDY

REPORTED HISTORY:

Low back pain, muscle strain left arm, left knee surgery 1983, right knee pain.

INTERPRETATION:

HEAD AND NECK:

There is hyperthermia over the forehead which can be seen with chronic sinus, headache and allergy conditions. This may not be clinically significant.

There is perioral hyperthermia, R>L, which is consistent with dental/periodontal pathology. Additionally, this finding correlates with the bilateral submandibular-cervical lymphatic drainage patterns.

There are inflammatory thermal patterns over the TMJ regions bilaterally which may correlate with joint dysfunction though the symptoms are not reported. There are irregular areas of hyperthermia over the posterior-lateral neck regions, R>L, which are consistent with myofascial dysfunction. These are not reported as regions of concern and may not be clinically significant.

THYROID:

No thermal asymmetry is identified.

CAROTID ARTERIES:

The region of the right and left carotid artery shows linear hyperthermia, which raises the question of inflammation possibly related to elevated CRP levels. Further evaluation maybe warranted, particularly if there is family history of stroke or cardiovascular disease.

CHEST:

There are no thermal findings suggestive of cardiovascular disease. Note: Lack of thermal findings does not rule out evolving cardiac pathology. An abnormal lipid profile and/or a strong family history may warrant additional studies.

BACK:

There are irregular areas of hyperthermia over the levators, supraspinatae, infraspinatae, rhomboids and trapezius, R>L, which are consistent with myofascial dysfunction. These are not reported as regions of concern and may not be clinically significant.

No thermal corollary for the low back pain.

ABDOMEN:

Mild inflammation is seen in the upper, mid abdomen and right lateral abdomen.

UPPER EXTREMITIES:

There is no thermal evidence of brachial plexus or radicular pathology.

There is asymmetrical hyperthermia over the medial wrists L>R, and right forearm which may be compensatory due to the left arm strain.

LOWER EXTREMITIES:

There is no thermal evidence of radicular pathology.

There is asymmetrical hyperthermia over the right lateral calf, right inferior knee, ankles L>R, palmar aspect of the feet L>R, which is compatible with myofascial dysfunction and joint inflammation and correlates with the

reported right knee pain.

RECOMMENDED FOLLOW-UP:

1. Suggest clinical correlation of thermal findings with patient's history and symptoms.
2. Recommend ongoing consultation with his physician or qualified health professional regarding dietary, nutritional and lifestyle practices that support essential good health.

Thank you for your kind referral,

Jeanne Stryker, MD
Diplomate American Board of Radiology

Disclaimer: The telemedicine system can fail due to circumstances the provider cannot control- for example, telecommunication interruption, power failure, software and remote equipment failure. The telemedicine system may relay information that is not accurate- for example, colors may be distorted, files may be incomplete. Thermography is an adjunct to mammography and does not replace mammography. A negative thermogram, mammogram and ultrasound do not preclude biopsy based on clinical condition.

DESCRIPTION OF THE CLINICAL THERMAL IMAGING STUDY

The patient above was examined by digital infrared thermal imaging using a high-resolution thermographic camera specific for clinical applications. Standardized thermography protocols were implemented which are designed to optimize clinical correlation of thermal patterns.

Medical imaging using infrared thermography captures the naturally occurring infrared emissions from the human body. These emissions vary in intensity and distribution over each body region and can be detected as thermal patterns of skin temperature. Advanced digital cameras as used in this study display these patterns as high-resolution color images in which colors represent various temperatures.

The resultant images reflect underlying neurovascular physiology and allow identification of asymmetric, abnormal or suspicious thermal patterns over a specific area or region of interest. Such patterns or changes over time may represent abnormal physiology or function. Thermal analysis of an imaging study allows objective clinical correlation by the physician and contributes to the decision-making process regarding therapy, additional testing and diagnosis.

Breast Thermography

Likewise, breast thermography is an adjunctive physiological assessment that is achieved by creating each person's unique baseline pattern via an initial and recommended three month follow-up test to assess thermal stability. Once established, monitoring thermal stability is achieved by comparison to this baseline at any time in the future.

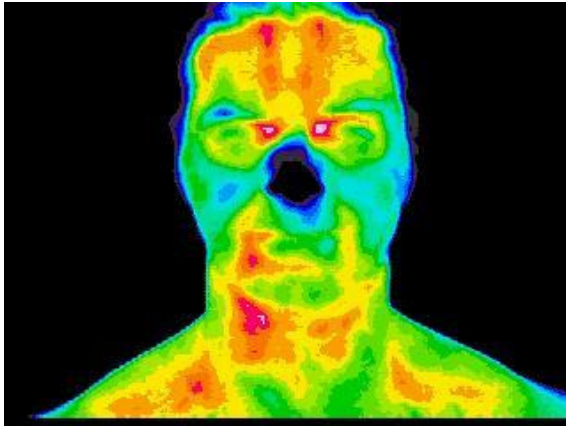
Such monitoring affords detection of even subtle thermal changes that, although not diagnostic, may precede anatomical findings by years and prompt early investigation and prevention. Thereby, breast imaging can be integrated as indicated with diagnostic anatomical tests such as ultrasound and mammography. Close follow-up and clinical correlation of thermal findings by the patient's physician is always recommended.

Study Outcome

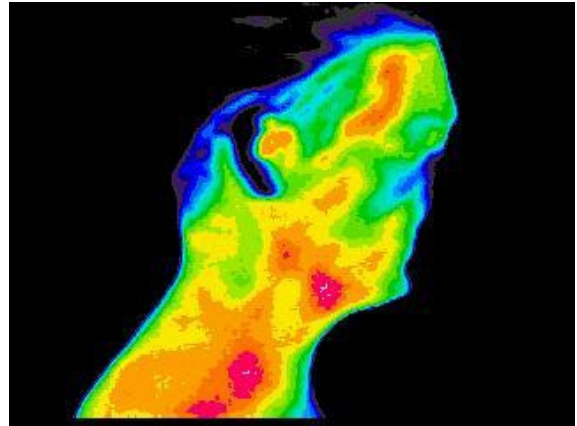
This study provides adjunctive clinical information and recommendations based solely upon the images and patient information provided, to support the patient's physician in medical evaluation and management.

Patient's Name [REDACTED]
Patient ID PriPat17031964
Date of Birth 03/17/1964
Referring Practitioner Patrick Price, DC

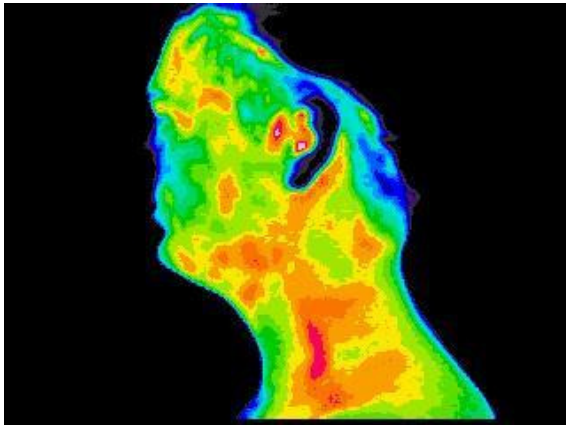
Report Date 12/09/2009
Study Date 12/04/2009
Thermographer Kathy Markham, CCT
Reporting Physician Jeanne Stryker MD



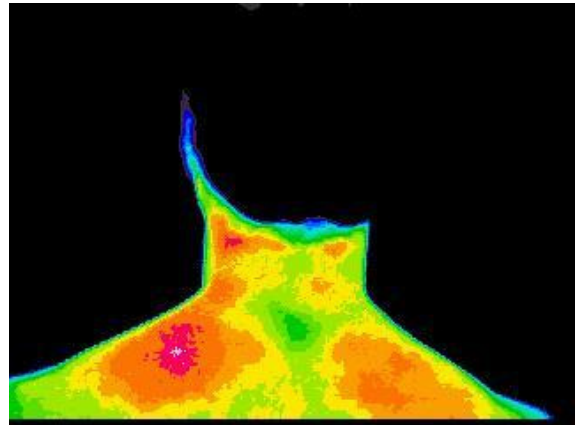
Head, Anterior



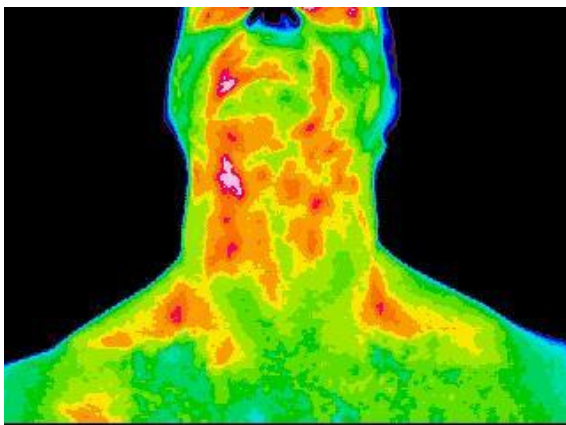
Head, Lateral Right



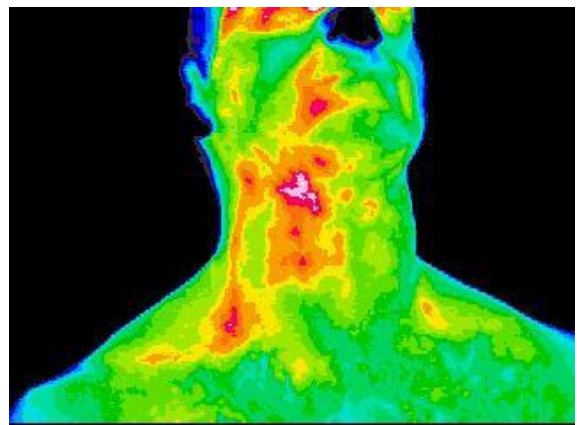
Head, Lateral Left



Neck, Posterior



Thyroid, Anterior

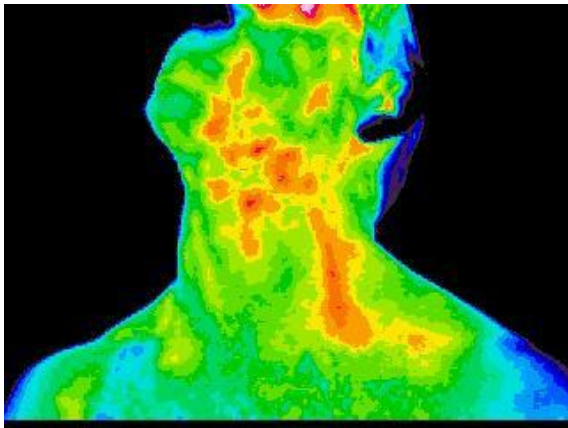


Thyroid, Right Oblique

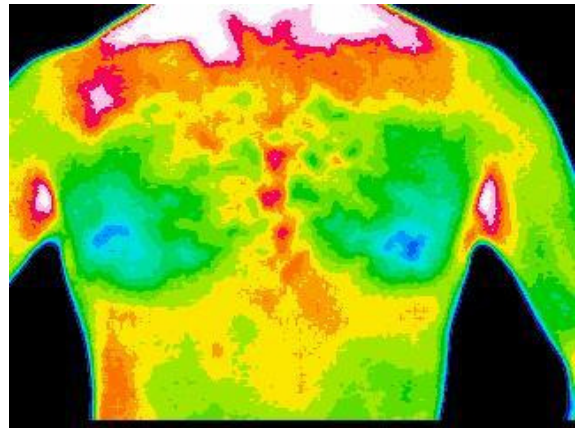


Patient's Name [REDACTED]
Patient ID PriPat17031964
Date of Birth 03/17/1964
Referring Practitioner Patrick Price, DC

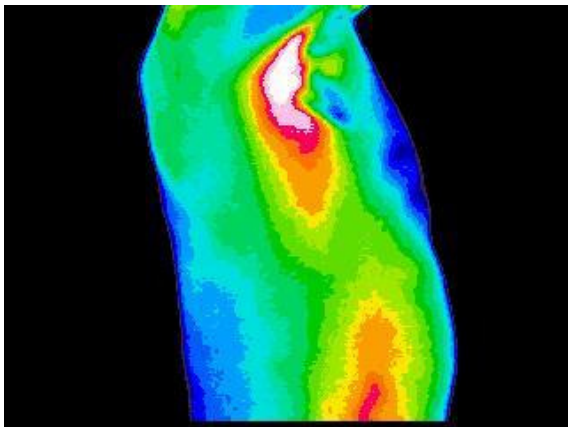
Report Date 12/09/2009
Study Date 12/04/2009
Thermographer Kathy Markham, CCT
Reporting Physician Jeanne Stryker MD



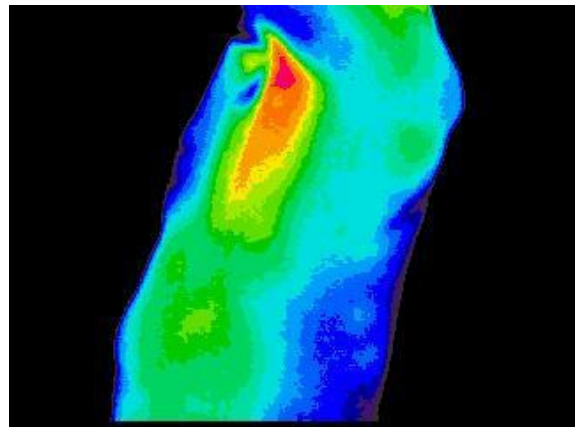
Thyroid, Left Oblique



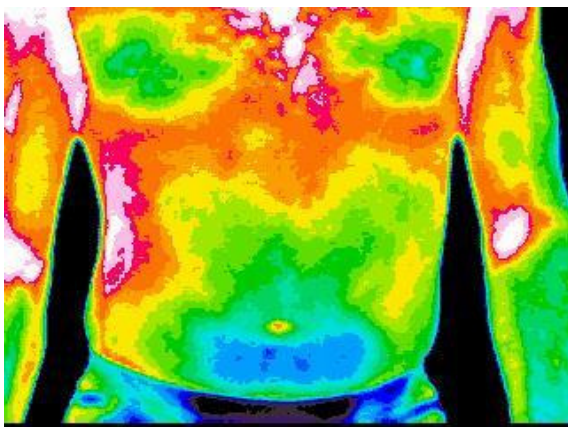
Chest, Anterior



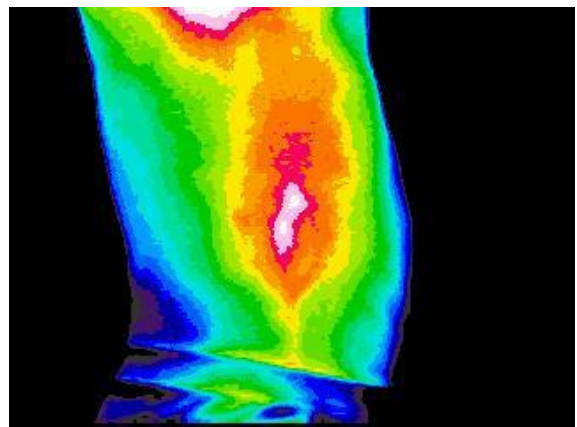
Chest, Lateral Right



Chest, Lateral Left



Abdomen, Anterior

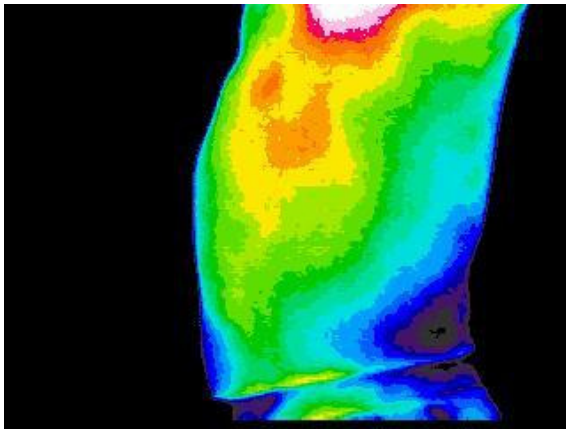


Abdomen, Lateral Right

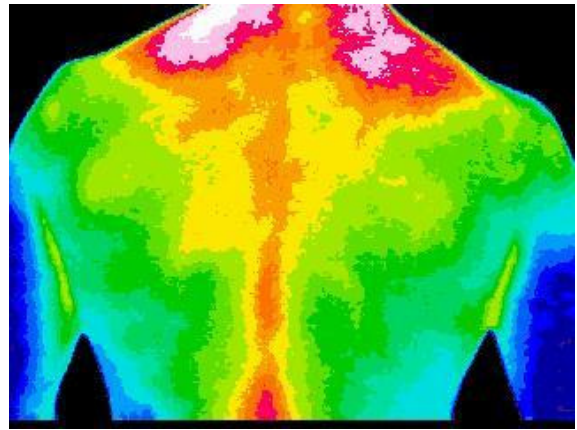


Patient's Name [REDACTED]
Patient ID PriPat17031964
Date of Birth 03/17/1964
Referring Practitioner Patrick Price, DC

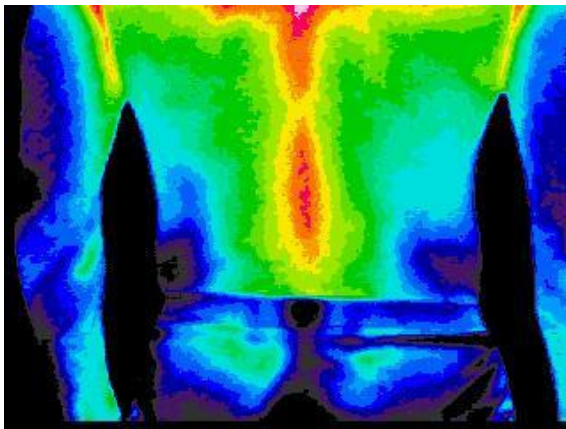
Report Date 12/09/2009
Study Date 12/04/2009
Thermographer Kathy Markham, CCT
Reporting Physician Jeanne Stryker MD



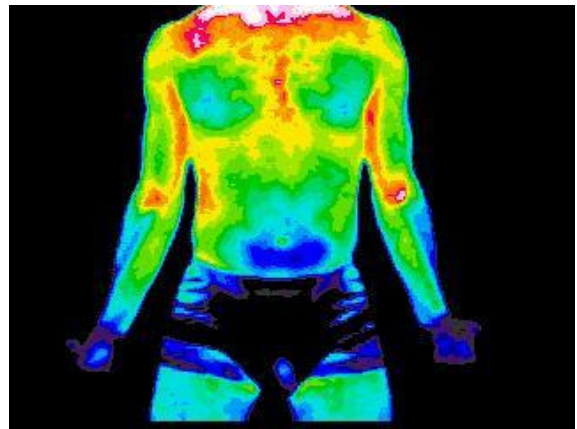
Abdomen, Lateral Left



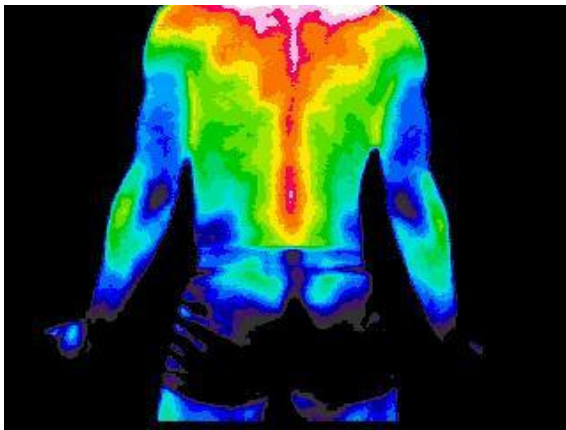
Back, Upper



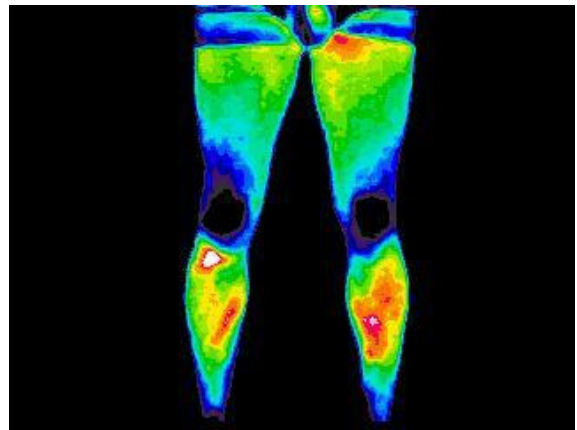
Back, Lower



Trunk, Anterior



Trunk, Posterior

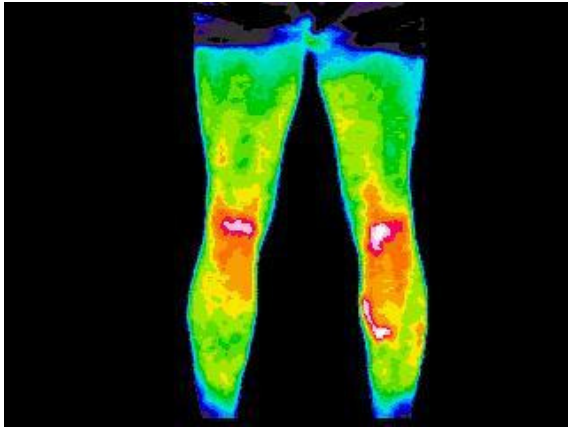


Legs, Anterior

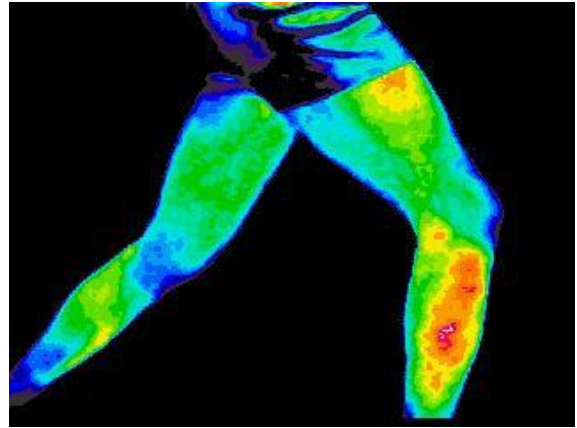


Patient's Name [REDACTED]
Patient ID PriPat17031964
Date of Birth 03/17/1964
Referring Practitioner Patrick Price, DC

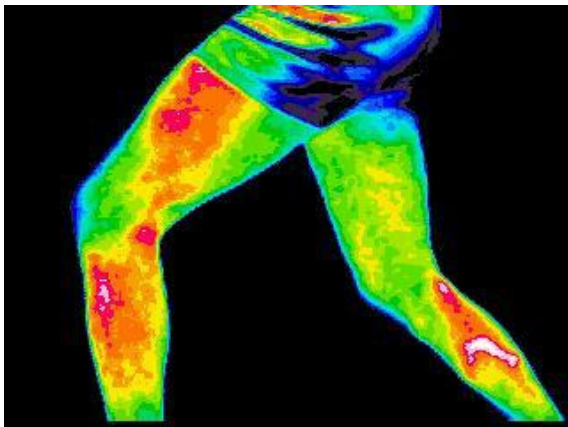
Report Date 12/09/2009
Study Date 12/04/2009
Thermographer Kathy Markham, CCT
Reporting Physician Jeanne Stryker MD



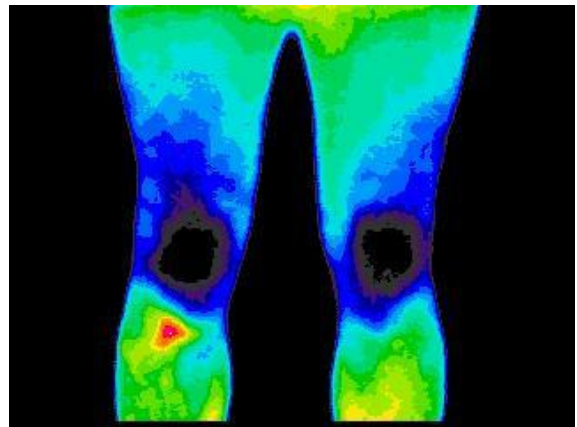
Legs, Posterior



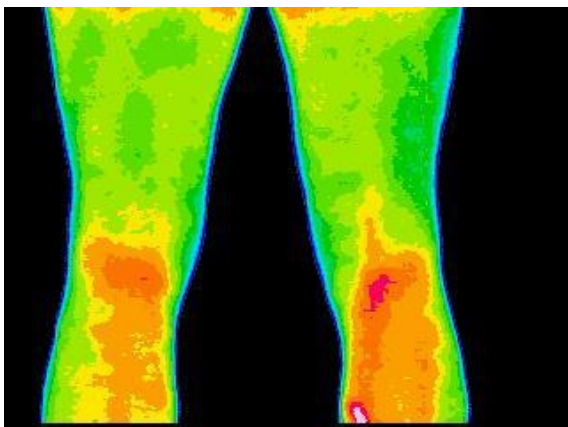
Legs, Lateral Right



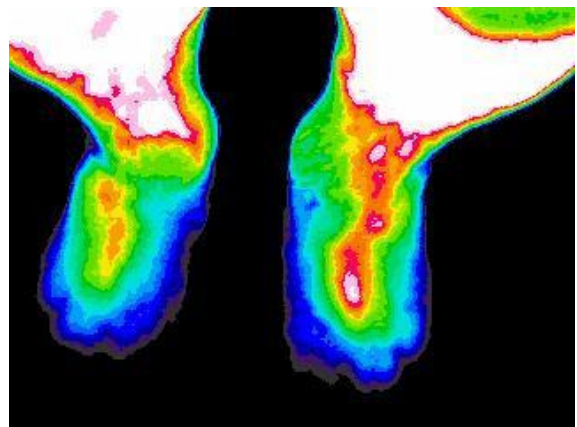
Legs, Lateral Left



Knees, Anterior



Knees, Posterior

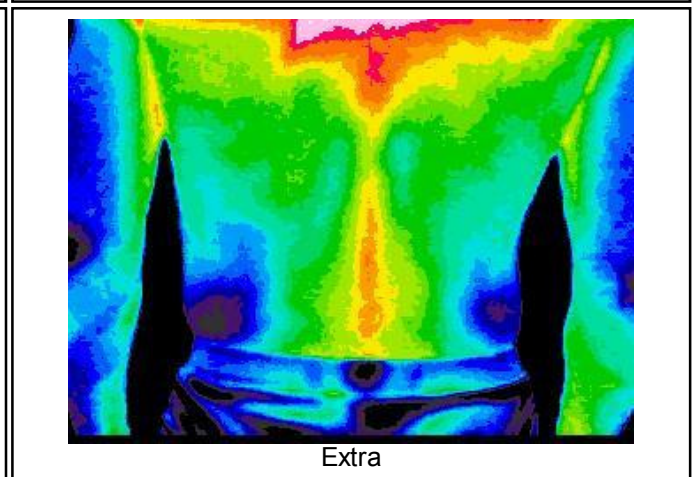
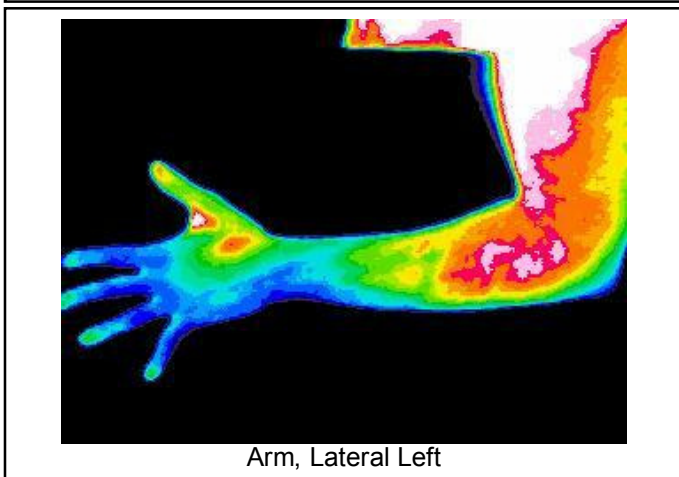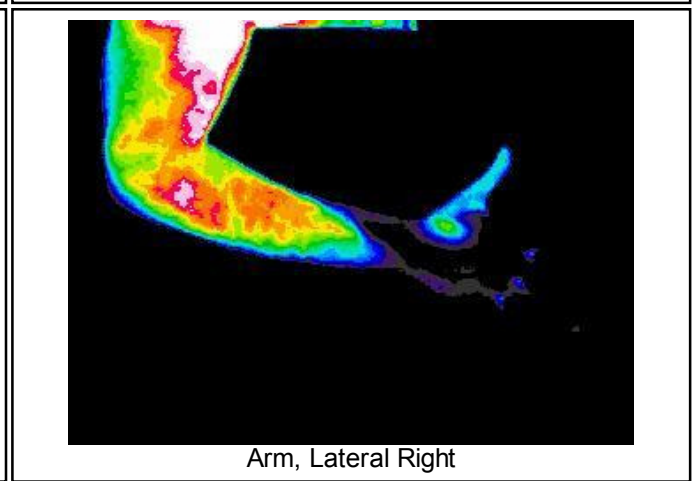
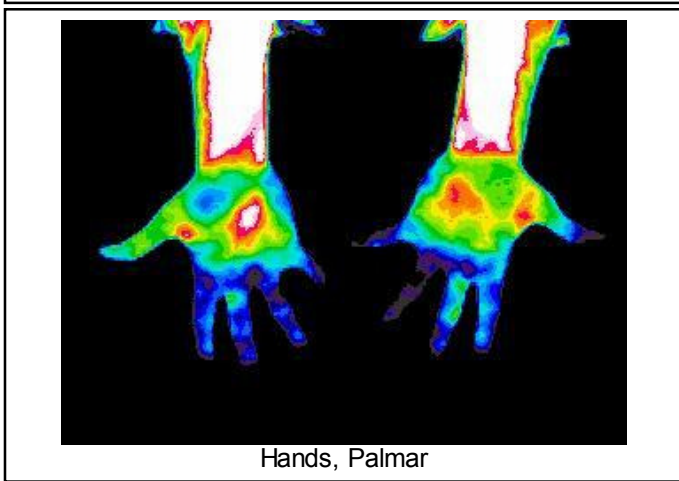
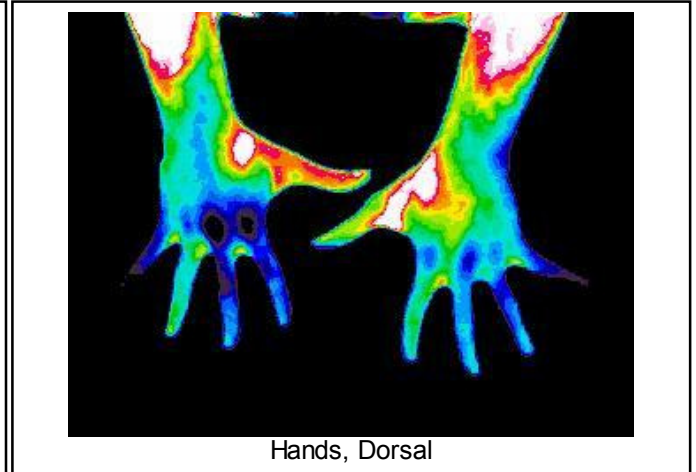
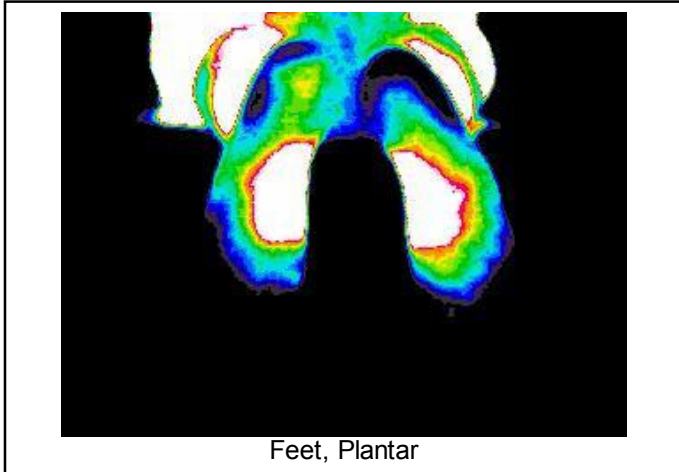


Feet, Dorsal



Patient's Name [REDACTED]
Patient ID PriPat17031964
Date of Birth 03/17/1964
Referring Practitioner Patrick Price, DC

Report Date 12/09/2009
Study Date 12/04/2009
Thermographer Kathy Markham, CCT
Reporting Physician Jeanne Stryker MD



Patient's Name [REDACTED]
Patient ID PriPat17031964
Date of Birth 03/17/1964
Referring Practitioner Patrick Price, DC

Report Date 12/09/2009
Study Date 12/04/2009
Thermographer Kathy Markham, CCT
Reporting Physician Jeanne Stryker MD

